

## Valsalva haemorrhagic retinopathy after push-ups

Mohd Hassan, Iqbal Tajunisah

Lancet 2011; 377; 504

Published Online

January 20, 2011

DOI:10.1016/S0140-6736(10)60677-0

Department of Ophthalmology, Faculty of Medicine, University of Malaya, 50603, Kuala Lumpur, Malaysia (M Hassan M Ophth, I Tajunisah FRCS)

Correspondence to: Dr Iqbal Tajunisah, Department of Ophthalmology, Faculty of Medicine, University of Malaya, 50603, Kuala Lumpur, Malaysia [tajun69@yahoo.com](mailto:tajun69@yahoo.com)

An 18-year-old man presented with sudden painless blurring of vision in the right eye, after a few rounds of push-up exercises. He was a college student. Our patient had no history of vascular disease or blood dyscrasias. His right vision was 20/200, and his left vision was 20/20. Retinal examination of the right eye showed a crescent shaped subhyaloid haemorrhage overlying the macula (figure A). Whole blood count, prothrombin time, and activated partial thromboplastin time, were within normal limits. A Nd:YAG laser hyaloidectomy was done, and 3 months later our

patients' right vision had improved to 20/40 (figure B). Valsalva retinopathy occurs because of a sudden rise in intraocular venous pressure, causing retinal capillaries to spontaneously rupture. Push-up exercises are Valsalva manoeuvres that increase intrathoracic pressure against a closed glottis, causing diminished venous return to the heart, reduced stroke volume, and an increase in venous system pressure. The outcome of Valsalva haemorrhagic retinopathy is generally good, with newer treatments such as laser hyaloidectomy improving recovery time.

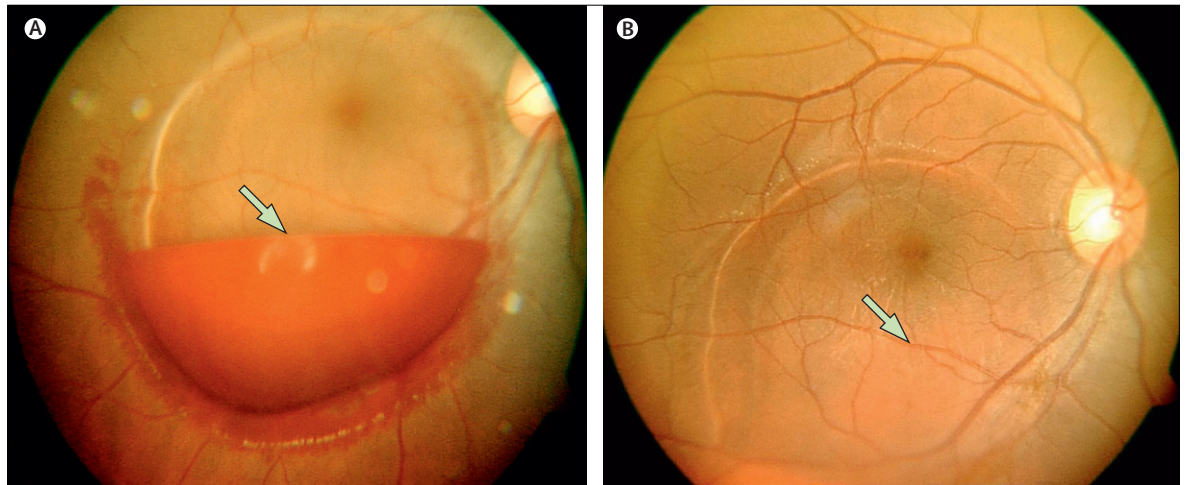


Figure: Retina fundus photographs of the right eye

(A) Crescent shaped subhyaloid haemorrhage overlying the macula (arrow). (B) Shows resolving subhyaloid haemorrhage (arrow) 3 months after Nd:YAG laser treatment.